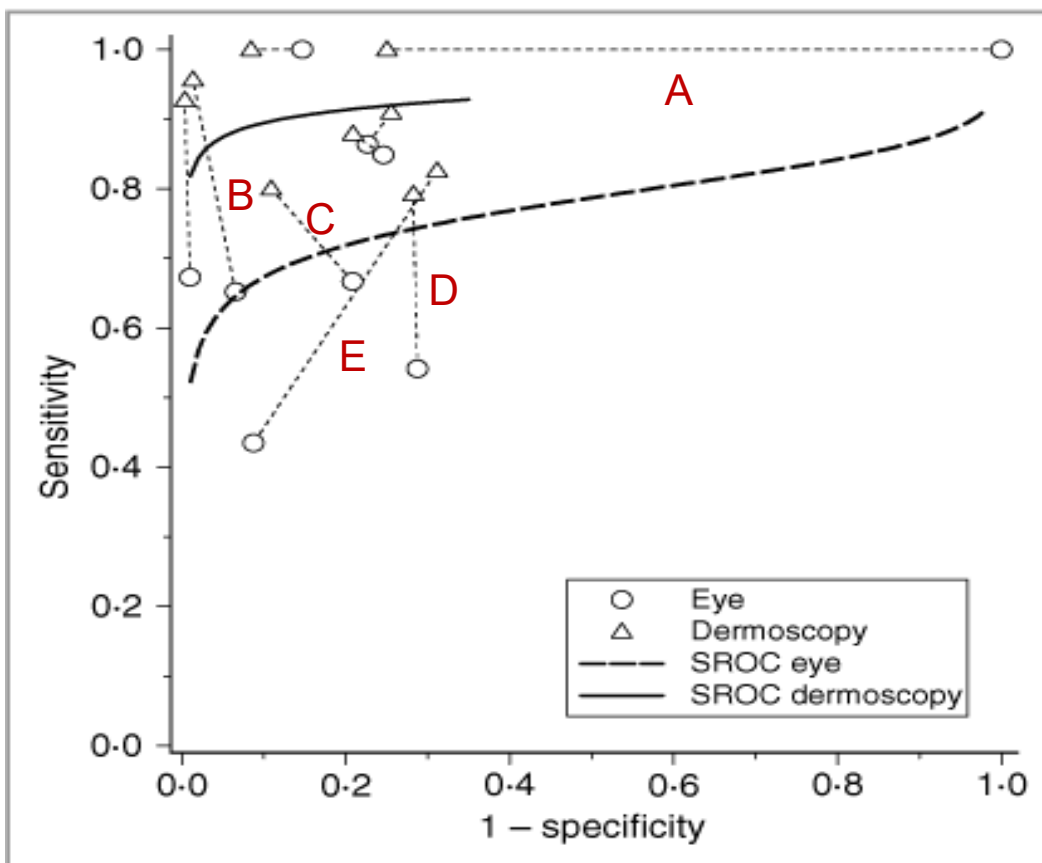


4.6 Dermoscopy versus Naked Eye for Diagnosing Melanoma

Dermatologists often are asked to evaluate suspicious looking moles to estimate the likelihood of malignant melanoma. Although this has traditionally been done with the naked eye, there is some evidence that a magnifying device called a dermoscope may improve discrimination.

As was shown in Chapter 4, one way to summarize results of multiple studies of diagnostic test accuracy is to plot the results on an ROC plane. Vestergard et al[1] did exactly that in a systematic review of 9 studies that compared the accuracy of dermoscopy with naked eye examination for diagnosing malignant melanoma. For each study, the authors plotted two points on the ROC plane – one for naked eye examination and one for dermoscopy. Dermoscopy performed unequivocally better in 7 of the 9 studies. (SROC stands for Summary ROC curve, the ROC curve that best fits the points taking sample sizes into account.)



Of the 5 studies with letter labels, dermoscopy performed unequivocally better than Eye in 4. In which of the 5 labeled studies (A,B,C,D,E) was that not the case? Explain your answer.

1. Vestergaard ME, Macaskill P, Holt PE, Menzies SW. Dermoscopy compared with naked eye examination for the diagnosis of primary melanoma: a meta-analysis of studies performed in a clinical setting. *Br J Dermatol.* 2008;159(3):669-76.